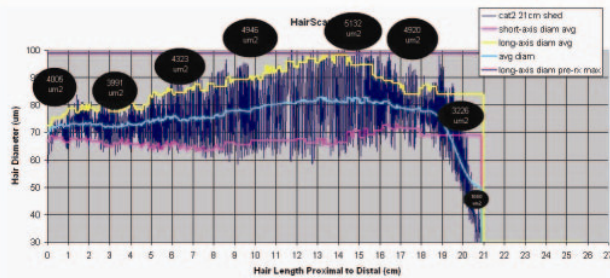


HairScan™ HAIR SHAFT MORPHOLOGY MAPPING

Same-Hair-Shaft Growth Pattern Changes As An Early Indicator Of LaserCap Efficacy

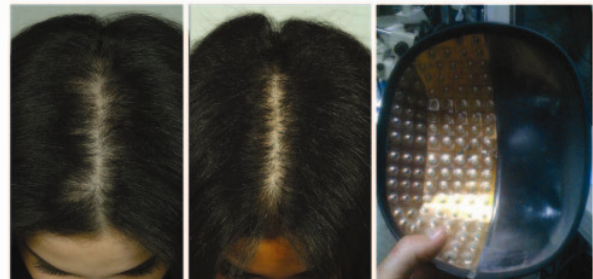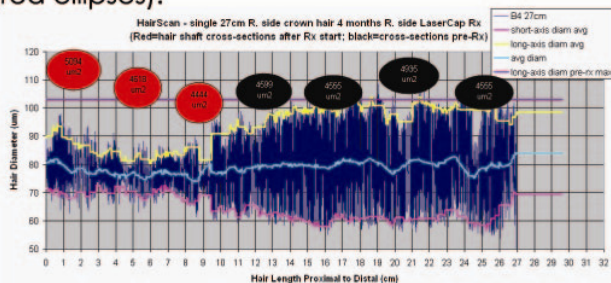
HairScan is an unprecedented hair growth analysis research tool in development by LaserCap creator **Michael Rabin, MD** and internationally recognized hair restoration physician **Robert Haber, MD** to measure same-hair-shaft (intra-cycle) growth pattern changes at a micron level in response to LaserCap. HairScan requires only a few strands of hair sent to our central lab, is completely non-invasive and hassle-free for the patient, and takes physician or staff only seconds to obtain the hair sample. HairScan may be performed before initiating LaserCap treatment to establish a patient's baseline hair growth patterns and then repeated as early as 30 days into treatment.

BASELINE "NORMAL" HAIRSCAN – 21cm complete anagen hair with telogen bulb; patient of Paul Cotterill, MD: early female pattern hair loss.



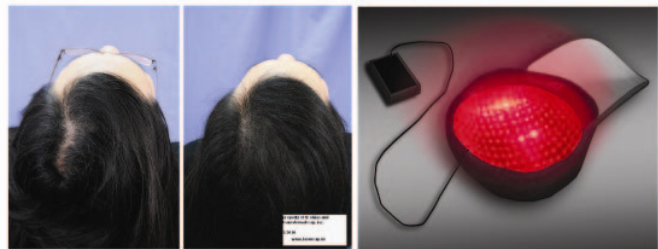
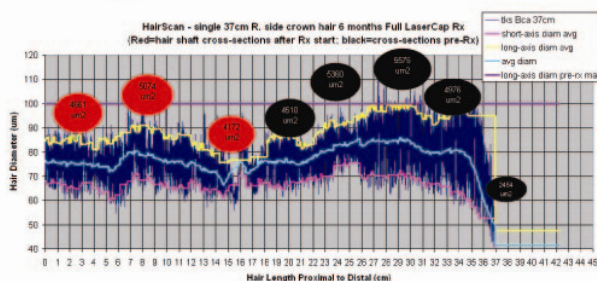
- Anagen tip (hair's birth) at 21cm.
- Max. long-axis diameter (yellow) at 14cm is 100um, with slow decrease to around 72um at 0cm, roughly 2mm from telogen bulb.
- Flat short-axis diameter (magenta) throughout (excluding early anagen), 65-70um range.
- Max. cross-sectional area at 14cm is 5132um² with long/short diameter of 100um/65um=1.5; hair becomes almost round by telogen.

INTRA-TREATMENT HAIRSCAN WITH BEFORE/AFTER PHOTO- 27cm cut (no anagen tip or telogen bulb) hair from Rx side crown after 1/2 head illumination LaserCap x 4 month; Patient of Bob Haber, MD: early female pattern hair loss. Note abrupt change in both long and short axis diameters (yellow and magenta) at 9cm, along with associated hair shaft rounding and trend of increasing cross-sectional area (red ellipses).



1/2 HEAD ILLUMINATION LASERCAP PATIENT OF ROBERT HABER MD

INTRA-TREATMENT HAIRSCAN WITH BEFORE/AFTER PHOTO- 37cm complete anagen hair (no telogen bulb) from crown of TK Shiao, MD after LaserCap x 6 months; MPH. Note abrupt change in long-axis diameter (yellow) at 14cm and trend of increasing cross-sectional area (red ellipses).



TK SHIAO, MD IS THE LASERCAP PATIENT

SEE US AT BOOTH#48 FOR MORE DETAIL; ISHRS BOSTON 2010

Patents pending, Copyright 2010 Transdermal Cap, Inc. (dba The LaserCap Co.) www.lasercap.us

(Over)